ARTICLE IN PRESS

The Journal of Foot & Ankle Surgery xxx (2011) 1–5

Contents lists available at ScienceDirect

The Journal of Foot & Ankle Surgery

journal homepage: www.jfas.org

Case Reports and Series

Missing the Lisfranc Fracture: A Case Report and Review of the Literature

Jordy van Rijn, MD [1], Desirée M.J. Dorleijn, MD [2], Bastiaan Boetes, MD [2], Saskia Wiersma-Tuinstra, MD [2], Sjors Moonen, PhD [1]

[1] Department of Orthopaedics, Amphia Hospital, Breda, The Netherlands
[2] Department of Orthopaedics, IJsselland Ziekenhuis, Capelle aan den IJssel, The Netherlands

ARTICLE INFO

Level of Clinical Evidence: 4
Keywords:
diagnosis
injury
metatarsal
midfoot
radiograph
surgery
tarsometatarsal
trauma

ABSTRACT

Injuries to the tarsometatarsal joint are infrequent and the presentation varies. The radiologic evaluation can be difficult, and injuries are missed initially in up to one third of cases. A 60-year-old female sports instructor presented to the emergency department with a Lisfranc fracture dislocation of the foot as result of an indirect trauma. The patient attended to a hospital the day she sustained the injury, where the Lisfranc fracture was missed. At our hospital, the patient underwent immediate restoration of the dislocation. Because of swelling, internal fixation was applied 2 weeks later. Postoperatively, the patient was mobilized in a non–weight-bearing plaster cast for 6 weeks, continued by progressive weight-bearing in a walker. The fixation screws were removed 3 months after surgery. Lisfranc fractures are rare injuries and can be missed at first sight. Careful clinical examination and radiographs in 3 different planes are required to identify the injury. Computed tomography might be helpful when the findings from the above-mentioned examinations are inconclusive. Operative treatment, including anatomic reduction and fixation, is required in almost all cases to achieve the best satisfactory result. Long-term complications include secondary arthritis and foot deformities, which can be treated by foot ortheses or arthrodesis.

Fracture dislocation of the tarsometatarsal (Lisfranc) joint is an uncommon foot injury, occurring at a rate of 1 per 55,000 to 60,000 annually (1–3). It constitutes 0.1% to 0.9% of all fractures (4). The diagnosis can be difficult because of subtle signs at examination and radiologic evaluation. Up to one third of these injuries are missed on the initial presentation (4–7). Missed Lisfranc fractures can lead to foot complaints owing to osteoarthritis and foot deformities (7,8).

We describe a case of an initially missed Lisfranc dislocation fracture and review the published data on the presentation, diagnosis, and management.

Case Report

A 60-year-old female sports instructor presented to the emergency department after jumping a ditch 1 day before. The left foot and ankle were injured, weight-bearing was no longer possible, and the left foot had begun to swell. She had attended the local hospital that day where radiographs of the left foot and ankle were performed. She was diagnosed with a sprain, and a pressure dressing was applied. She was advised to consult her general practitioner the next day.

Address correspondence to: Jordy van Rijn, MD, Department of Orthopaedics, Amphia Hospital, 21 Molengracht, PO Box 90158, Breda 4800 RK The Netherlands.
E-mail address: JRijn@amphia.nl (J. van Rijn).

Because of persistent pain, an inability to bear weight, and the foot deformity, she visited our emergency department 1 day after the initial trauma. On physical examination, the anatomy of the left foot was different from that of the right foot. A prominent medial cuneiform and navicular bone marked a large tender swelling on the medial aspect of the foot. The circulation and neurologic examination findings were normal. The skin was intact.

A review of the radiologic images taken elsewhere displayed enlargement of the first midtarsal space and displacement of all cuneiform bones and the cuboid toward the medial side. A Lisfranc fracture dislocation type A was diagnosed. New radiographs in 3 dimensions (Fig. 1) and a computed tomography (CT) scan (Fig. 2) were taken. The CT scan showed multiple avulsion fragments at the base of the metatarsal bones and confirmed the dislocation of the tarsal bones.

A closed reduction of the Lisfranc fracture dislocation was performed immediately, and a non–weight-bearing cast was applied. The postreduction radiograph is shown in Fig. 3. The leg was kept elevated, and patient underwent surgical treatment after the swelling had subsided 2 weeks later.

Operative Technique

Under image intensifier guidance, closed reduction to an anatomic alignment was performed using a bone reduction clamp. A Kirschner wire was drilled through a stab incision from the medial cuneiform to

1067-2516/$ - see front matter © 2011 by the American College of Foot and Ankle Surgeons. All rights reserved.
doi:10.1053/j.jfas.2011.10.048

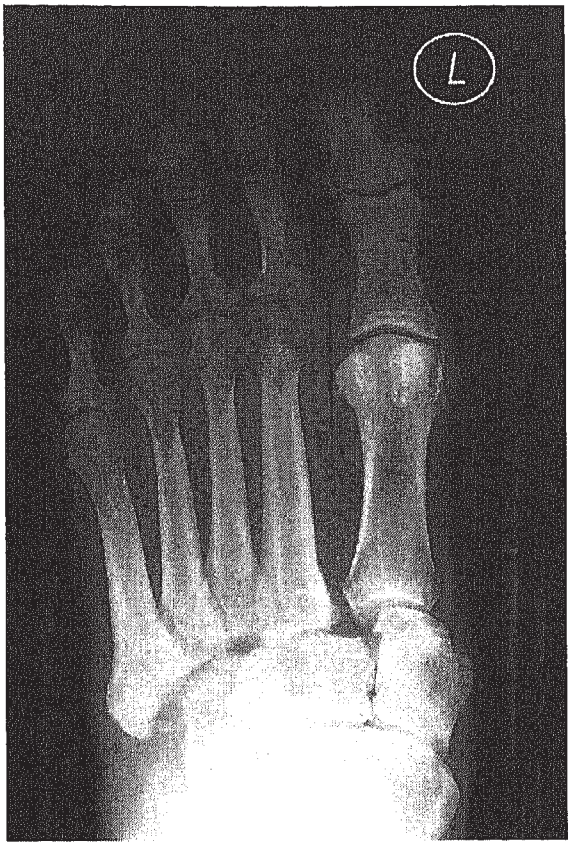

Fig. 1. Preoperative anteroposterior radiographic view.

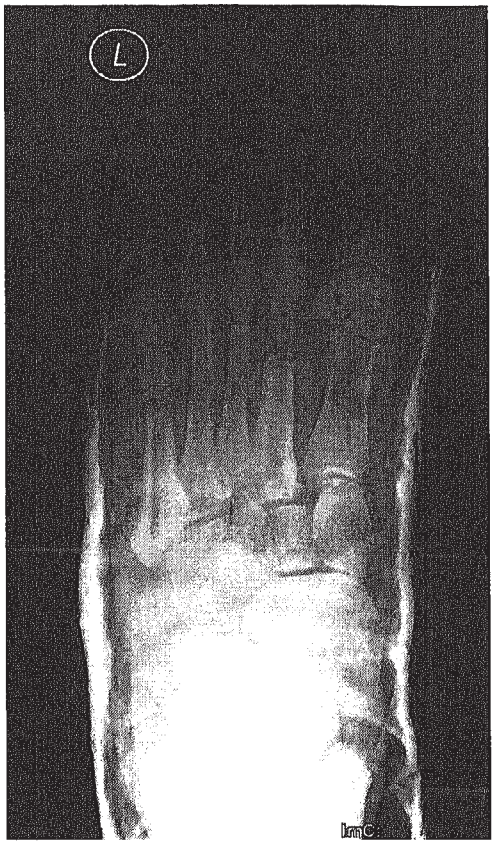

Fig. 3. Preoperative postreduction anteroposterior radiographic view in a non–weight-bearing cast.

the second metatarsal. A cannulated compression screw was drilled over the Kirschner wire to secure the reduction. A second Kirschner wire was placed from the first metatarsal to the medial cuneiform and a screw inserted. Anatomic reduction was confirmed with anteroposterior (AP) and lateral radiographs before wound closure (Fig. 4). Because the fifth metatarsal had reduced spontaneously once the second metatarsal was reduced and the reposition was stable, no Kirschner wire fixation was applied to the lateral site of the foot. A non–weight-bearing plaster cast was applied for 6 weeks.

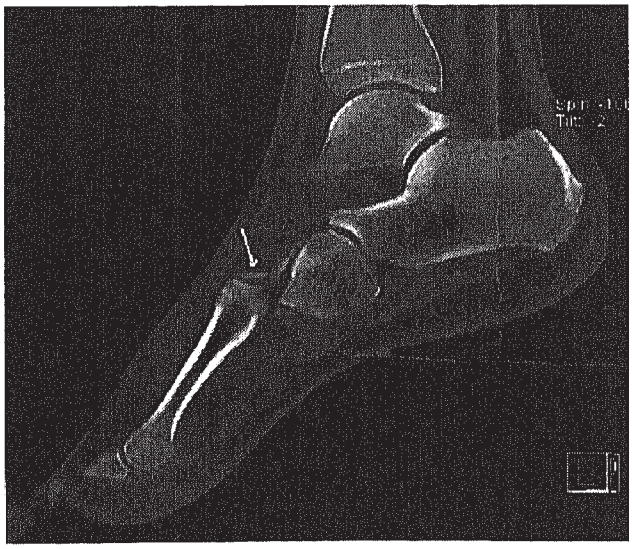

Fig. 2. Preoperative lateral computed tomographic view. Note the multiple avulsion fragments at the base of the metatarsal bones.

Postoperative Therapy

After 6 weeks of non–weight-bearing in a plaster cast, the patient was allowed to progressively bear weight in a walker. The screws were removed 3 months later (Fig. 5). During follow-up, the patient's mobilization improved only slightly. A CT scan to ascertain a good position 6 months after surgery showed a few loose bony fragments but an acceptable position of the treated metatarsals.

Discussion

The tarsometatarsal joint is named after the French surgeon Jacques Lisfranc (1790 to 1847) in Napoleon's army who introduced a new amputation technique of the forefoot at this level to treat gangrenous injury. This technique does not require a bony osteotomy (9,10).

Anatomy

The Lisfranc joint consists of 5 metatarsals that articulate with 3 cuneiforms and the cuboid. It can be divided into 3 parts. The medial column is formed by the first cuneiform and the first metatarsal, and the median column by the second and third cuneiform and the second

Fig. 4. Postoperative anteroposterior radiographic view confirming anatomic reduction.

Fig. 5. Postoperative anteroposterior radiographic view after removal of the screws 3 months after surgery.

and third metatarsals. The lateral column is formed by the cuboid and fourth and fifth metatarsals (8,10). The second metatarsal is the keystone of the Lisfranc joint. It is recessed between the medial and lateral cuneiform bones and attached to the medial cuneiform by the oblique Lisfranc ligament. This solitary ligament connects the first ray to the middle and lateral columns of the foot, and injury to this ligament results in instability. If the second metatarsal base area is disrupted, significant dislocation can occur in the coronal plane (1,7,8,10,11).

Trauma Mechanism

Lisfranc injuries can be caused by direct or indirect trauma. Direct injuries are often a result of high-energy injuries such as motor vehicle collisions. These injuries can be complicated by extensive soft tissue damage, open wounds, vascular compromise, and compartment syndrome (1,6,12). Depending on the point of application of the force to the foot, this direct type of injury can produce a variable pattern of dislocation (5).

A trivial trauma (e.g., missing the last step of a stairway) can result in an indirect Lisfranc fracture. Indirect trauma results from a rotational force to the forefoot with a fixed hindfoot or axial loading on a plantar flexed, fixed foot. Dorsal metatarsal dislocation occurs usually in this type of injury, because the resistance is lowest at the dorsal site of the foot (1,5–7). The dislocation is often associated with fractures, most commonly of the base of the second metatarsal and cuboid bone (1,5).

Clinical Presentation

Patients present with pain localized in the midfoot, swelling, and inability to bear weight after the trauma. The foot may appear deformed compared with the other foot, such as was present in our case. Plantar ecchymosis and a linked toe dislocation could alert the physician (2,6,10). In some cases, a "toe-up-sign" will be present, which can be a result of tibialis anterior tendon interposition forcing the first toe to point dorsally (13). Particularly in the case of direct trauma, circulatory disturbances can occur from lesions of the blood vessels or arterial spasm (8).

Classification

The classification according to Quenu and Kuss (14) was commonly used in the classification of a Lisfranc joint injury in the past. Their classification divided the injury into 3 groups (homolateral, isolated, and divergent). Although simple to apply, it did not include all displacement varieties. Therefore, the current classification is that derived from Hardcastle et al (3). The injuries are divided in more or less the same 3 categories, but the different planes that could apply in fracturing are respected. Type A represents total incongruity of the tarsometatarsal joint, such as was present in our case. Displacement is in 1 plane, which can be sagittal, coronal, or combined. In type B, partial incongruity of the joint is present. There are 2 types of partial displacement: medial and lateral. Medial displacement affects the first metatarsal, either isolated or combined with the second, third, or fourth metatarsal. The lateral displacement affects 1 or more of the

lateral metatarsals, but the first metatarsal is unaffected. Type C is referred to as divergent. Partial or total incongruity can be present. The first metatarsal is displaced medially and any of the other metatarsals could be displaced laterally.

Radiologic Examination

In significant trauma to the foot, radiographs in 3 different planes (AP, lateral, and 30° oblique) should be taken, preferably weight-bearing views. The base of the second metatarsal, which reaches about 1 cm proximally relative to the base of the first metatarsal and about 0.5 cm proximally relative to the base of the third metatarsal, plays a significant role in the stabilization of the Lisfranc joint. The medial aspect of the base of the second metatarsal should align with the medial border of the middle cuneiform.

On the AP view, any diastasis of more than 2 mm between the base of the first and second metatarsal suggests a Lisfranc injury (10,12). On the lateral view, the superior border of the base of the first metatarsal should align with the superior border of the medial cuneiform (10). On the oblique views, the medial border of the fourth metatarsal should align with the medial border of the cuboid (9,10,12). A "fleck" sign seen on the AP view is pathognomonic for a Lisfranc injury and represents an avulsion fracture of the base of the second metatarsal or medial cuneiform resulting from traction of the Lisfranc ligament. It is radiologically evident in 90% of the patients with a Lisfranc fracture (5,8,10,12,15). A compression fracture of the cuboid or avulsion fractures of the base of the second metatarsal should raise suspicion of a Lisfranc fracture (9,11,15).

If weight-bearing views cannot be obtained, stress views should be taken. These are best obtained with anesthesia to minimize pain. With the hindfoot stable, prosupination and abduction and adduction stress can be applied to the forefoot. A displacement of more than 2 mm in the joint represents ligamentous instability (11). Radiologic clues, together with the clinical findings, are helpful in diagnosing the Lisfranc fracture. In subtle abnormalities, CT represents a useful tool (7,10,11). Magnetic resonance imaging can identify isolated tears of the Lisfranc ligament (10).

Treatment

Only mild sprains to the Lisfranc joint that are anatomically stable and nondisplaced should be treated with immobilization. Treatment should consist of a non–weight-bearing cast for a minimum of 6 weeks, followed by progressive weight-bearing in a cast for an additional 4 to 6 weeks. The cast can be removed when full weight-bearing in the cast is painless (10,15,16).

Patients with displaced or unstable Lisfranc injuries should undergo reduction (closed or open) and operative fixation (10,17). The best predictors of a satisfactory result after tarsometatarsal dislocations are primary anatomic reduction and internal fixation (5,8,15,18–20).

Closed reduction can be achieved by hanging the foot by the toes using finger traps and, thus, providing longitudinal traction with plantar flexion and supination of the forefoot, followed by dorsiflexion and pronation (3,5,6,20). Closed reduction can fail because of interposed soft tissue (anterior tibial tendon or long peroneal tendon) and small bony fragments, in which case, open reduction should then be performed (5,18,21). Some investigators believe the reduction should always be open because congruencies of the surface of the joint can be achieved best with open reduction (18).

Closed reduction and casting without operative fixation has shown poor results, because maintenance of the reduction is difficult and secondary displacement often occurs. Even after secondary surgery, the results have still been poorer than after primary reduction and operative fixation (5,11). Different operative methods to establish anatomic reduction have been described. Kirschner wires have been used for fixation, but with reported problems of pin migration, pin tract infection, and a loss of reduction (5,18). Although the evidence is not significant, currently, the use of screws is preferred (22). They provide more stability, and the reduction of the joint can be facilitated by gentle compression of the joint (18,19). Ly and Coetzee (23) concluded that primary partial arthrodesis provided better results than open reduction and internal fixation in ligamentous Lisfranc injuries. However, a study by Mulier et al (24) showed that irrespective of the type of injury, open reduction and internal fixation provided a better outcome than primary complete arthrodesis (all 5 metatarsals).

In some cases, surgery can be postponed to allow for subsidence of the soft tissue swelling (19,25), such as was also done in our case.

Surgical Technique

Operative reduction and fixation best proceeds from a medial to a lateral direction. Starting at the medial side, the first and second metatarsal and medial cuneiform are reduced and fixed (with either Kirschner wires or screws) (19,21). If spontaneous reduction of the lateral metatarsals does not occur, the fifth metatarsal can be fixed to the cuboid and calcaneus with a Kirschner wire (19,22). It is usually not necessary to transfix the second, third, and fourth metatarsals (1).

Complications

Short-term complications after a Lisfranc injury include foot compartment syndrome, deep venous thrombosis infection, and wound complications. Long-term complications include painful hardware or hardware failure, midfoot arthritis and flatfoot deformity, and instability (5,7,9,10,19,26). If a nonanatomic reduction is achieved after open reduction and fixation, the prevalence of post-traumatic osteoarthritis is significantly greater at up to 60% (19). Secondary osteoarthritis can be managed by complete or partial arthrodesis (15,22).

Prognosis

Although Aitken and Poulsen (1) found that patients' functional results were good, despite missed Lisfranc fractures and persistent dislocations, other studies have shown a worse outcome after delayed treatment compared with direct treatment (1,4). The type of injury also plays an important role. Type B results in a worse functional outcome than type C or A. This is probably because this partial dislocation can easily be missed on radiologic examination and treated after a delay (27).

A delay in treatment of more than 6 months provides a poorer functional outcome. Patients were more often unable to return to their preinjury level of activity (28).

Secondary corrective arthrodesis for malunited fracture-dislocations has a significantly worse result than primary open reduction and internal fixation of Lisfranc fracture-dislocations. Therefore, a wait-and-see attitude should not be adopted. However, for initially overlooked or misdiagnosed tarsometatarsal fracture-dislocations, secondary corrective arthrodesis results in a significant reduction of pain and improvement in function (4). Most patients still require shoe modifications or orthoses (5).

Conclusion

The Lisfranc fracture-dislocation results from severe direct or indirect injury to the foot. It should be suspected in every patient

presenting with swelling of the foot and an inability to bear weight. The type of fracture should be established from the clinical findings and the findings from radiographs in 3 different planes. Avulsion fractures, (slight) deterioration of the normal anatomic borders, and CT scanning could be of help in diagnosing the Lisfranc fracture. Treatment involves surgery in which anatomic reduction and internal fixation with Kirschner wires or screws is most important and is the best predictor of a satisfactory result.

References

1. Aitken AP, Poulson D. Dislocations of the tarsometatarsal joint. J Bone Joint Surg Am 45-A:246–260, 1963.
2. English TA. Dislocations of the metatarsal bone and adjacent toe. J Bone Joint Surg Br 46:700–704, 1964.
3. Hardcastle PH, Reschauer R, Kutscha-Lissberg E, Schoffmann W. Injuries to the tarsometatarsal joint: incidence, classification and treatment. J Bone Joint Surg Br 64:349–356, 1982.
4. Rammelt S, Schneiders W, Schikore H, Holch M, Heineck J, Zwipp H. Primary open reduction and fixation compared with delayed corrective arthrodesis in the treatment of tarsometatarsal (Lisfranc) fracture dislocation. J Bone Joint Surg Br 90:1499–1506, 2008.
5. Myerson MS, Fisher RT, Burgess AR, Kenzora JE. Fracture dislocations of the tarsometatarsal joints: end results correlated with pathology and treatment. Foot Ankle 6:225–242, 1986.
6. Perron AD, Brady WJ, Keats TE. Orthopedic pitfalls in the ED: Lisfranc fracture-dislocation. Am J Emerg Med 19:71–75, 2001.
7. Philbin T, Rosenberg G, Sferra JJ. Complications of missed or untreated Lisfranc injuries. Foot Ankle Clin 8:61–71, 2003.
8. Goossens M, De Stoop N. Lisfranc's fracture-dislocations: etiology, radiology, and results of treatment: a review of 20 cases. Clin Orthop Relat Res 176:154–162, 1983.
9. Sharma D, Khan F. Lisfranc fracture dislocations—an important and easily missed fracture in the emergency department. J R Army Med Corps 148:44–47, 2002.
10. Trevino SG, Wade AM, Early JS, Vallurupalli S. Lisfranc fracture dislocation. Available at http://emedicine.medscape.com/article/1236228-overview. Updated October 6, 2009. Last accessed December 5, 2011.
11. Reid JJ, Early JS. Fractures and dislocations of the midfoot and forefoot. In: *Rockwood and Green's Fractures in Adults*, ed 7, edited by RW Bucholz, JD Heckman, CM Court-Brown, P Tornetta, 2009, Lippincott Williams & Wilkins, Philadelphia, 2009.
12. Tadros AM, Al-Hussona M. Bilateral tarsometatarsal fracture-dislocations: a missed work-related injury. Singapore Med J 49:e234–e235, 2008.
13. Karaindros K, Arealis G, Papanikolaou A, Mouratidou A, Siakandaris P. Irreducible Lisfranc dislocation due to the interposition of the tibialis anterior tendon: case report and literature review. Foot Ankle Surg 16:e68–e71, 2010.
14. Quenu E, Kuss G. Etude sur les luxations du metatarse. Rev Chir Paris 39:281, 1909.
15. Canale ST, Beaty JH. *Campbell's Operative Orthopaedics*, Mosby Elsevier, New York, 2007.
16. Nunley JA, Vertullo CJ. Classification, investigation, and management of midfoot sprains: Lisfranc injuries in the athlete. Am J Sports Med 30:871–878, 2002.
17. Granberry WM, Lipscomb PR. Dislocation of the tarsometatarsal joints. Surg Gynecol Obstet 114:467–469, 1962.
18. Arntz CT, Veith RG, Hansen ST Jr. Fractures and fracture-dislocations of the tarsometatarsal joint. J Bone Joint Surg Am 70:173–181, 1988.
19. Kuo RS, Tejwani NC, Digiovanni CW, Holt SK, Benirschke SK, Hansen ST Jr, Sangeorzan BJ. Outcome after open reduction and internal fixation of Lisfranc joint injuries. J Bone Joint Surg Am 82-A:1609–1618, 2000.
20. Mulier T, Reynders P, Sioen W, van den Bergh J, de Reymaeker G, Reynaert P, Broos P. The treatment of Lisfranc injuries. Acta Orthop Belg 63:82–90, 1997.
21. Randt T, Dahlen C, Schikore H, Zwipp H. [Dislocation fractures in the area of the middle foot—injuries of the Chopart and Lisfranc joint]. Zentralbl Chir 123:1257–1266, 1998.
22. Myerson MS. The diagnosis and treatment of injury to the tarsometatarsal joint complex. J Bone Joint Surg Br 81:756–763, 1999.
23. Ly TV, Coetzee JC. Treatment of primarily ligamentous Lisfranc joint injuries: primary arthrodesis compared with open reduction and internal fixation. A prospective, randomized study. J Bone Joint Surg Am 88:514–520, 2006.
24. Mulier T, Reynders P, Dereymaeker G, Broos P. Severe Lisfranc's injuries: primary arthrodesis or ORIF? Foot Ankle Int 23:902–905, 2002.
25. Benejam CE, Potaczek SG. Unusual presentation of Lisfranc fracture dislocation associated with high-velocity sledding injury: a case report and review of the literature. J Med Case Reports 2:266, 2008.
26. Zwipp H, Rammelt S, Holch M, Dahlen C. [Lisfranc arthrodesis after malunited fracture healing]. Unfallchirurg 102:918–923, 1999.
27. Gaweda K, Tarczynska M, Modrzewski K, Turzanska K. An analysis of pathomorphic forms and diagnostic difficulties in tarso-metatarsal joint injuries. Int Orthop 32:705–710, 2008.
28. Calder JD, Whitehouse SL, Saxby TS. Results of isolated Lisfranc injuries and the effect of compensation claims. J Bone Joint Surg Br 86:527–530, 2004.